



STABILITY OF INTRAOSSEOUS DENTAL IMPLANTS  
WITH GUIDED BONE REGENERATION  
(*IN VIVO* EXPERIMENT IN DOGS)

J. INDJOVA<sup>1</sup>, KH. FAKIH<sup>1</sup>, D. SIVREV<sup>2</sup>, D. YOVCHEV<sup>3</sup>  
& TS. CHAPRAZOV<sup>4</sup>

<sup>1</sup>Department of Oral and Maxillofacial Surgery, <sup>3</sup>Department of Imaging and Oral Diagnostics, Faculty of Dental Medicine, Medical University, Sofia, Bulgaria; <sup>2</sup>Department of Anatomy, Medical Faculty, Trakia University, Stara Zagora; <sup>4</sup>Department of Veterinary Surgery, Faculty of Veterinary Medicine, Trakia University, Stara Zagora; Bulgaria

**Summary**

Indjova, J., Kh. Fakih, D. Sivrev, D. Yovchev & Ts. Chaprazov, 2014. Stability of intraosseous dental implants with guided bone regeneration (*in vivo* experiment in dogs). *Bulg. J. Vet. Med.*, 17, No 1, 50–60.

Three different protocols for dental implantation: immediate (ImI), delayed (DI) and conventional (CI) were used. The primary stability is important for the secondary stability of implants. The purpose of the experiments was to monitor the stability of ImI, DI and CI following guided bone regeneration (GBR). A total of 18 implants were placed in the alveoli of 9 extracted premolars of the lower jaw of three mixed breed dogs. GBR was performed with a combination of Bio Oss<sup>®</sup> and Emdogain<sup>®</sup> and the Bio Gide<sup>®</sup> membrane. Control GBR was performed with coagulum and the same membrane. The stability of the implants was measured with Osstell<sup>®</sup> ISQ. The primary stability of the three types of implants was high, and differed statistically significantly ( $P < 0.05$ ). By the end of the first month after the placement, the stability of ImI and DI was reduced. The secondary stability of ImI and DI increased substantially ( $P < 0.05$ ) by the end of the third month both with regard to primary stability and stability by the end of the first month. The primary stability of intraosseous implants was a prerequisite for a high secondary stability. The decline in stability by the end of the first month after implantation was not an obstacle to achieve a high secondary stability.

**Key words:** guided bone regeneration, implants, stability, xenografts

INTRODUCTION

Stability is the most concise but accurate enough term to describe a successful treatment using intraosseous implants. The biological substrate is of primary significance for implant stability. This however,

does not underestimate implant design and coating or operative precision. The latter are not part of this research's incentives.

The stability of an implant is primary and secondary. The primary, initial stabi-

lity (at the moment of implant placement) is of mechanical nature. It is due to the incorporation of the implant in the jaw bone and largely depends on the cortical bone. Secondary stability is a function of repair process beginning after implant placement. It is biologically determined and associated mainly with cancellous bone and cancellous bone events (Atsumi *et al.*, 2007). After the implant is loaded, the bone regenerates and undergoes remodelling with regard to implant surface connection and proper osteointegration (Atsumi *et al.*, 2007). Primary or mechanical stability is the necessary condition for occurrence and development of secondary or biological stability (Sennerby & Roos, 1998). The mechanical stability and osteointegration (being a sequel to primary and measure of secondary implant stability) are mainly a function of several quantitative and quality features of jaw bone, such as bone volume and bone structure – bone density, cortical thickness (Roze *et al.*, 2009).

A number of methods for preservation and/or augmentation of jaw bone for intraosseous implant placement are available. Some examples are the atraumatic tooth extraction and GBR with osseous coagulum and barrier membrane, or a combination of bone graft and membrane. A number of bone grafts have been used. Bio Oss is one of the most extensively explored xenografts with acknowledged osteoconduction properties (Baldini *et al.*, 2011). A number of attempts were accomplished for improvement of its manipulation and biological properties through combinations with fibrin sealant (Carmagnola *et al.*, 2000), autogenous bone (Hallman *et al.*, 2002). We have previously reported that the GBR with a mixture of Bio Oss and Emdogain resulted in a more significant lamellar bone accumulation

compared to the independent use of Bio Oss + Emdogain (Indjova *et al.*, 2013). No data are however available whether this combination applied via GBR, influences the stability of implants depending on the implantation protocol.

Three methods for dental implantation were used – immediate, delayed/immediately delayed and conventional.

The immediate placement of implant(s) was performed immediately after tooth extraction. It shortened the treatment by 3 to 6 months after extraction and was reported to restrict alveolar bone resorption (Bhola *et al.*, 2008).

The contact between implant surface and extraction socket ensures a better osteointegration (Lundgren *et al.*, 1992). Clinical practice has evidenced that in immediate implantation, the mismatch of the shape of the extraction socket and implant shape often resulted in a slit around different parts of the implant – platform, neck, body. Depending on its vertical and horizontal dimensions, delayed or absent bone regeneration, epithelium migrate into the slit, difficulties in obtaining reliable primary stability are present and thus, osteointegration is postponed, does not occur or is faulty (Scarano *et al.*, 2006). In such instances, GBR with graft and/or membrane confines the growth of epithelial and connective tissue structures in the slit (Lang *et al.*, 1994).

Mainly marginal slits with horizontal dimensions of 1–4 mm have been studied (Wilson *et al.*, 1998). Opinions are conflicting – some assume that spontaneous repair is possible for defects with horizontal dimensions of up to 2.5 mm (Botticelli *et al.*, 2004) while others affirm that GBR should be applied (Wilson *et al.*, 1998). Thus, the problem for treatment of defects with horizontal dimensions over 3 mm remains still open.

The investigations on the marginal slit and the lack of regular contact between implant surface and alveolar wall were mainly aimed at possibilities for spontaneous or guided regeneration (West *et al.* 2007). Apart the regenerative resp. histomorphological aspect of the problem, the monitoring and the evaluation of stability of implants in extraction sockets following GBR are also essential for the clinical practice.

For the other two approaches for implantation – immediately delayed and conventional which takes place 4 to 8 weeks and at least 3 months after tooth extraction, respectively, the problems in achieving primary stability are related to resulting reduction of alveolar bone volume. For keeping of volume, either atraumatic extraction and/or GBR with membrane or membrane + graft are used (Atnoun *et al.* 2007).

Along with the necessity for a biological substrate of adequate amount and quality, intraosseous implants also require objective measurement of their stability. Techniques for implant stability measurement are a valuable reference point of occurring peri-implant bone repair events before the placement of the abutment and the prosthesis. Various tests and methods for implant stability assessment are applied. Some of them, i.e. the percussion test, are subjective, others do not allow stability monitoring (torque test, cutting torque resistance test) and a third group including the reverse torque test, are destructive and inapplicable in a clinical setting (Meredith, 1998; Atsumi *et al.*, 2007; Sennerby & Meredith, 2008).

For the needs of clinical practice the applied method should be objective, quantitative, rapid, and suitable for use in clinical conditions, non-invasive, non-destructive and atraumatic with regard to

the bone-implant interface. A method responding to all these requirements is the resonance frequency analysis (RFA) (Al-Nawas *et al.*, 2007). The force applied on implants has precisely defined parameters, equal for each measurement. The subjective element is completely absent. The sensitivity of the last generation Osstell® ISQ, which uses magnetic pulses is evaluated as very high (Sennerby & Meredith, 2008). It allows measuring the stability of implants.

The information about objective comparative monitoring of implant stability placed in tooth sockets with different substrates for GBR through one of aforementioned methods is scarce.

The purpose of the present experiment was to follow up the time course of stability after placement of immediate, delayed and conventional implants in a dog model.

## MATERIALS AND METHODS

The experiments were conducted in the Veterinary dental cabinet, Department of Veterinary Surgery, Faculty of Veterinary Medicine at the Trakia University – Stara Zagora.

All surgical interventions were performed in strict compliance with the Law on Veterinary Medical Activities, Ordinance 25/10.06.2005, and Directive 2010/63/EU on the protection of animals used for scientific purposes. Three mixed-breed dogs, aged 1 to 3 years were included. The initial health status of dogs was evaluated as good, and the dentition – intact. The experiments, part of Grant No. 17/2013, Medical University – Sofia were approved as compliant to national and international ethical standards regarding animal experimentation (decision of the Research Ethics Commission to the

Medical University – Sofia, protocol 5/17.04.2013).

*Preoperative preparation*

Twenty-four hours before the surgery, each dog received an intramuscular injection of amoxicillin and clavulanic acid (Synulox, Pfizer Animal Health, UK) at a dose of 8.75 mg/kg. Premedication was done with 0.02 mg/kg atropine sulfate (Atropin, Sopharma Ltd, Sofia, Bulgaria). The induction of anaesthesia was done 15 min later i. v. with 0.5 mg/kg diazepam (Diazepam, Sopharma Ltd, Sofia, Bulgaria) and 10 mg/kg ketamine hydrochloride (Anaket 10%, Richter Pharma AG, Austria). Maintenance of inhalation anaesthesia was performed with 1.2–3 vol% isoflurane (AErrane Inhalation vapour, liquid, Baxter d.o.o. Ljubljana, Slovenia).

*Intraoral preoperative preparation*

Immediately before the operation, the site was aseptically prepared by thorough cleaning of dental surfaces with 3% hydrogen peroxide and profuse washing with water, as well as scrubbing the mucosa and dental surfaces with povidone iodine (Iodseptadon 10%).

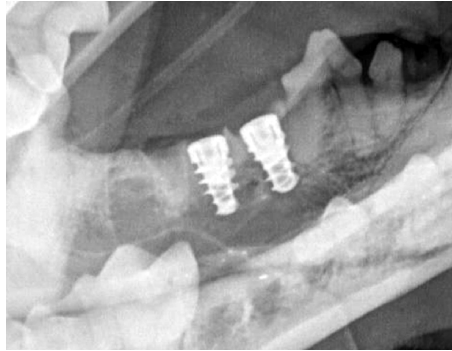
*Surgical interventions*

All operative interventions were performed aseptically by the same surgeon. In each dog, atraumatic extraction of the 3<sup>rd</sup> and 4<sup>th</sup> premolars on one side and the 4<sup>th</sup> premolar on the contralateral side of the mandible was done after mucoperiosteal flap preparation. After teeth extraction, three pairs of sockets were obtained in each dog. For the first socket, regeneration of defects occurred with osseous coagulum and for the other – with xenografts (Table 1). In each dog, two immediate (ImI – Fig. 1), two delayed (DI – Fig. 2) and two conventional (CI – Fig. 3) implants were placed at the proper time. All implants were of conical shape and equal dimensions: 4.2 mm diameter and 8 mm length (Alfa Gate Bioactive SCI 842). The total number of implants was 18 (6 per dog). Despite the purposefully selected conical shape of implants similar to that of tooth roots, a marginal slit up to 1 mm wide and up to 1.5 mm deep occurred between immediate implants and buccal and lingual alveolar wall, respectively. With a bone cutter, a part of the lingual wall of sockets for immediate implants and GBR with xenografts and membrane

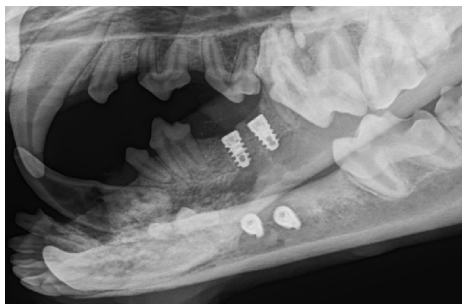
**Table 1.** Distribution of implants and measurements depending on the implantation approach and guided bone regeneration

	Implantation approach					
	Immediate (immediate implants)		Depayed-immediate (delayed implants)		Conventional (conventional implants)	
Guided bone regeneration	Bio Oss + Emdogain+ Bio Gide	Coagulum + Bio Gide	Bio Oss + Emdogain+ Bio Gide	Coagulum + Bio Gide	Bio Oss + Emdogain+ Bio Gide	Coagulum + Bio Gide
Number of implants	3	3	3	3	3	3
Number of measurements	9	9	9	9	9	9

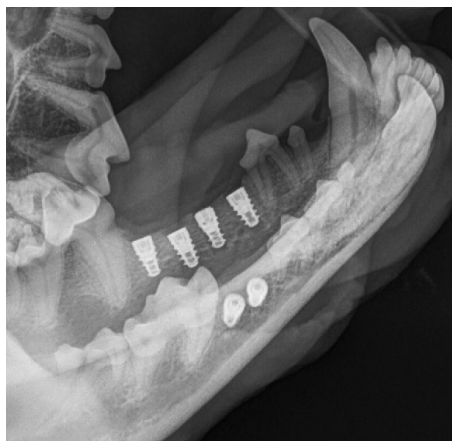was removed (Table 1). Thus, bone defects with horizontal size of 3–4 mm and depth 4 mm (measured with graduated



**Fig. 1.** Immediate implants.



**Fig. 2.** Delayed implants.



**Fig. 3.** Conventional implants.

probe, compass and ruler) were formed. The artificially enlarged slits were filled with a mixture of two xenografts – Bio Oss<sup>®</sup> (Geistlich Pharma AG) and Emdogain<sup>®</sup> (Straumann Emdogain<sup>®</sup>, Institut Staumann AG, Bazel/Switzerland).

The placed ImI together with the artificial bone defect were covered with resorbable membrane Bio Gide<sup>®</sup> (Geistlich Pharma AG). In one socket of the other two pairs of extraction sockets, a mixture of xenografts was placed, and the other remained filled with coagulum. All sockets were covered with resorbable membrane as per GBR principles. One month after the extraction, delayed implants were placed (two for each dog – one in an alveolus using GBR with coagulum; the other in a socket using GBR with aforementioned xenografts). Three months after extraction of premolars, the last two (conventional) implants were placed. For all three implantation protocols, each of the six implants was placed approximately in the middle of the respective socket at the level of vestibular cortical bone. Cover screws were placed on all implants. The flaps were replaced and sutured with interrupted non-absorbable sutures 4/0 Medicon ex to ensure a coated healing of implants and extraction sockets with GBR.

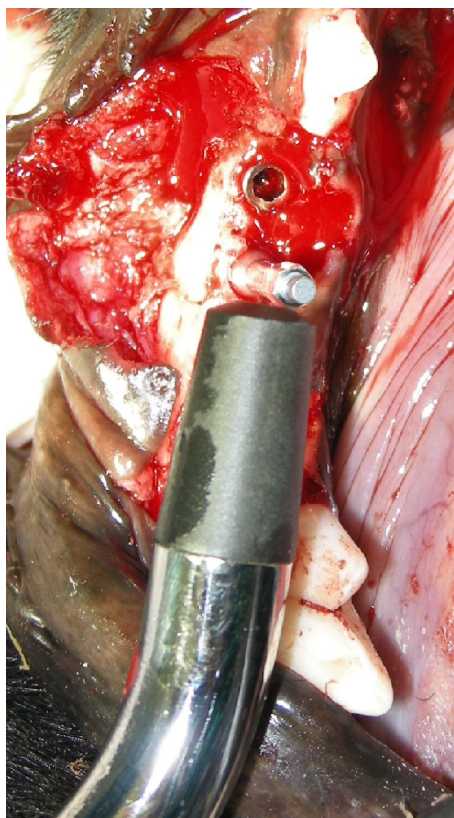
#### *Postoperative care*

Over 10 days after each surgery, each dog was i.m. treated with antibiotic Synulox (Pfizer Animal Health, UK) at a dose of 8.75 mg/kg. During the first 2 post operative days, dogs drank only water, and then were fed soft food for another 10 days. Oral hygiene was maintained until sutures removal by the 14<sup>th</sup> post operative day.

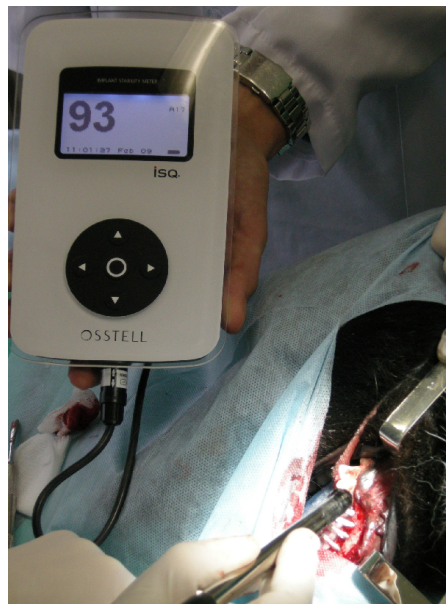#### *Implant stability measurements*

The stability of dental implants was evaluated by the newest version of the reso-

nance frequency analyzer Osstell® ISQ (Osstell Mentor™ Integration diagnostics; Osstell AB, Göteborg, Sweden). In this unit, the pulses are generated by a probe with built-in magnetic elements and are detected by a metal rod (SmartPeg), which is screwed on the implant and receives emitted signals (Fig. 4). Magnetic pulses are of 1 ms duration. They cause the SmartPeg to resonate. The effect is identical to horizontal loads borne by the functioning implant. The waves reflected by the resonating metal rod are detected by the measuring probe and displayed in numeric values by the instrument. The values reflect implant stability quotient



**Fig. 4.** Osstell ISQ probe and a SmartPeg mounted on the implant.



**Fig. 5.** Osstell ISQ instrument with a measured ISQ value on its display.

(ISQ) values (Sennerby & Meredith, 2008), which are standardised to provide a numerical expression of implant stability within a scale from 0 to 100 (Fig. 5). The higher the value, the higher the stability.

Three measurements in buccolingual direction were made on each implant, as per manufacturers' directions (Table 1).

#### *Statistical analysis*

Data were processed using descriptive statistics tools and submitted to either ANOVA or Kruskal-Wallis analysis at a level of significance  $P < 0.05$ .

## RESULTS

The measured primary stability values were high for all implants regardless of the used implantation protocol (immediate, delayed or conventional). The highest primary stability was exhibited by CI. It

was statistically significantly higher both vs ImI and DI ( $P < 0.05$ ). The stability of DI was lower than that of either ImI ( $P < 0.05$ ) or CI ( $P < 0.05$ ). These results were obtained for the two GBR types: GBR with coagulum and GBR with Bio Oss+Emdogain (Table 2).

The primary stability of ImI and DI decreased by the end of the first month ( $P < 0.05$ ).

The ISQ values for secondary stability after the 3<sup>rd</sup> experimental month were statistically significantly higher both than values by the end of the 1<sup>st</sup> month and primary stability values ( $P < 0.05$ ). The statement was true for healing with coagulum and with the participation Bio Oss+Emdogain (Table 2).

The comparative analysis of the effect of GBR with coagulum or Bio Oss+Emdogain on the stability of implants using three implantation protocols showed that:

- The primary and secondary stability of immediate implants were substantially higher for GBR healing with coagulum

compared to GBR with xenografts ( $P < 0.05$  and  $P < 0.001$ , respectively). There were no statistically significant differences between GBR types by the first experimental month ( $P > 0.05$ ; Table 3).

- For delayed implants, only secondary stability values differed considerably for GBR with coagulum ( $P < 0.001$ ). Although insignificant, minor differences were observed also for primary and first-month stability (Table 3).

Conventional implants healed by GBR with coagulum exhibited a substantially greater stability compared to those healed by GBR and xenografts ( $P < 0.001$ ; Table 3).

## DISCUSSION

In this study, the experiments were carried out on dog mandibles. Thus, we aimed to compare our data with those of other researchers having experimented on the same site (Caneva *et al.* 2010 a, b).

**Table 2.** Stability of implants depending on the implantation approach and guided bone regeneration (GBR) type, expressed in ISQ values over a 3-month period of observation. Data are presented as mean  $\pm$  standard deviation,  $n=9$

Stability	Implantation approach		
	Immediate implants	Delayed implants	Conventional implants
<i>Bio Oss+ Emdogain+ Bio Gide</i>			
Primary	81.56 <sup>a</sup> $\pm$ 1.33	71.56 <sup>b</sup> $\pm$ 1.24	88.44 <sup>c</sup> $\pm$ 1.33
By the 1 <sup>st</sup> month	66.78 <sup>h</sup> $\pm$ 1.09	66.11 <sup>h</sup> $\pm$ 1.17	–
Secondary (3 <sup>rd</sup> month)	86.89 <sup>k</sup> $\pm$ 1.69	86.33 <sup>l</sup> $\pm$ 1.41	–
<i>Coagulum + Bio Gide</i>			
Primary	83.11 <sup>d</sup> $\pm$ 1.62	72.33 <sup>e</sup> $\pm$ 1.41	95.67 <sup>f</sup> $\pm$ 1.32
By the 1 <sup>st</sup> month	66.89 <sup>h</sup> $\pm$ 2.03	67.67 <sup>h</sup> $\pm$ 2.12	–
Secondary (3 <sup>rd</sup> month)	92.11 <sup>m</sup> $\pm$ 1.76	90.67 <sup>n</sup> $\pm$ 1.66	–

The different superscripts within a row indicate statistically significant differences at  $P < 0.05$ .

**Table 3.** Stability of implants depending on the implantation approach and guided bone regeneration (GBR) type, expressed in ISQ values over a 3-month period of observation. Data are presented as mean  $\pm$  standard deviation, n=9

Stability	Guided bone regeneration		
	Bio Oss+ Emdogain+ Bio Gide	Coagulum+ Bio Gide	P
<i>Immediate implants</i>			
Primary	81.56 $\pm$ 1.33	83.11 $\pm$ 1.62	< 0.05
By the 1 <sup>st</sup> month	66.78 $\pm$ 1.09	66.89 $\pm$ 2.03	0.863
Secondary (3 <sup>rd</sup> month)	86.89 $\pm$ 1.69	92.11 $\pm$ 1.76	< 0.001
<i>Delayed implants</i>			
Primary	71.56 $\pm$ 1.24	72.33 $\pm$ 1.41	0.232
By the 1 <sup>st</sup> month	66.11 $\pm$ 1.17	67.67 $\pm$ 2.12	0.094
Secondary (3 <sup>rd</sup> month)	86.33 $\pm$ 1.41	90.67 $\pm$ 1.66	< 0.001
<i>Conventional implants</i>			
Primary	88.44 $\pm$ 1.33	95.67 $\pm$ 1.32	< 0.001
By the 1 <sup>st</sup> month	–	–	
Secondary (3 <sup>rd</sup> month)	–	–	

The high primary stability of all implants was anticipated. Similar data were already reported (Sennerby *et al.*, 2005) and findings were attributed to the relatively high density of the mandibular alveolar bone in dogs (Caneva *et al.* 2010 a, b).

Relatively lower primary stability quotients of delayed implants vs those of immediate and conventional types could be attributed to the cumulative effects of two traumas: tooth extraction and placement of xenografts, without leaving enough time to the organism to cope with it. The trauma from the preparation of the implantation bed in an environment with already reduced biological potential should be also considered. The local reactions after immediate and conventional implantations were different. After ImI placement, the traumatic effect of tooth extraction was not manifested. After CI implantation, not only had the tissue

reactions of extraction and xenografts abated, but regeneration was already far advanced (Piatelli *et al.*, 1999).

The highest primary stability quotient of conventional implants, which was statistically significantly higher than those of ImI and DI, could be attributed to the close contact of implant and cortical bone achieved with this approach. After preparation of gingivoperiosteal flap, cortical bone was clinically completely restored.

The reduced stability of ImI and DI by the end of the first post implantation month corresponded at a high extent to other reports (Rabel *et al.*, 2007). One month is a rather short period after implantation, when the traumatic consequences were not overcome, the biopotential of bone was not restored and its remodelling has not yet begun (Sennerby & Meredith, 2008).



The reduced stability of immediate and delayed implants by the end of the first month was not an obstacle for the subsequent increase in their stability. After the third post implantation month, the measured ISQ was considerably higher both vs primary stability and one-month stability values. This is associated to alveolar bone remodelling events. Osteointegration between the implant and the bone socket, and secondary stability has occurred (Akca *et al.*, 2006). In ImI and DI, the primary stability resulted from the mechanical bond between implant and cancellous bone, i.e. mechanical cancellous bone stability was observed. Over the 3-month period, the peri-implant cortical bone was restored (Carmagnola *et al.*, 2003). It is the primary source of stability (Sennerby & Meredith, 2008). Meanwhile, cancellous bone stability was transformed into biological cancellous bone stability by virtue of new bone formation and remodelling, and appearing osteointegration. Osteointegration is present over the entire length of the implant (Rocci *et al.*, 2003). This way, a cortical stability was added biological cancellous bone stability which has replaced the mechanical type of stability.

In this experiment on three dogs and 18 implants, their stability quotients were substantially higher in an environment of GBR with osseous coagulum than in cases of GBR with the xenograft combination Bio Oss+Emdogain.

Interventions for maxillary sinus floor augmentation with guided bone regeneration with Bio Oss have shown that even after 18 months or more, xenograft particles were not fully resorbed (Piattelli *et al.*, 1999). New bone, including mature mineralised lamellar bone with osteons and Haversian canals has formed, similar to what was observed in GBR with coa-

gulum. The presence of non-resorbed bone graft however, reduced the relative amount of newly formed bone (Hammerle *et al.* 1998). We suggested that the bone formed by its natural constituents and non-resorbed Bio Oss particles could be of inferior mechanical quality compared to newly formed bone from coagulum.

The comparison of implant stability quotients in the light of the limited number of experimental subjects (3 dogs, 18 implants of three types: immediate, delayed and conventional) should be done carefully without definite conclusions. The observed tendencies were in agreement were already reported data (Botticelli *et al.*, 2003, Caneva *et al.*, 2010a, b).

## CONCLUSION

The present *in vivo* experiment in dogs demonstrated high implant stability quotients for the 18 implants. This primary stability decreased by the end of the first month. This did not impede the occurrence of a high secondary stability by the end of the third month. The implant stability for guided bone regeneration with coagulum was superior to that of implants healed by GBR with Bio Oss+Emdogain xenografts.

## ACKNOWLEDGMENTS

The experiment have been financially supported by Grant No. 17/2013, Medical University – Sofia, Council of Medical Science.

## REFERENCES

- Akca, K., T. Chang, L. Tekdemir & M. Fanuscu, 2006. Biomechanical aspects of initial intraosseous stability and implant design: a quantitative micromorphometric analysis.

- Clinical Oral Implant Research*, **17**, 465–472.
- Al-Nawas, B., K. Groetz, H. Goetz, H. Duschner & W. Wagner, 2007. Comparative histomorphometry and resonance frequency analysis of implants with moderately rough surfaces in a loaded animal model. *Clinical Oral Implant Research*, **18**, 1–8.
- Atnoun, H., C. Chemaly & P. Missika, 2007. Bone substitutes. In: *Bone Augmentation in Oral Implantology*, Quintessence Publ, pp. 341–372.
- Atsumi, M., S. Park & H. Wang, 2007. Methods used to assess implant stability: current status. *International Journal of Oral and Maxillofacial Implants*, **22**, 743–754.
- Baldini, N., M. De Sanctis & M. Ferrari, 2011. Deproteinized bovine bone in periodontal and implant surgery. *Dental Materials*, **27**, 61–70.
- Bhola, M., A. Neely & Sh. Kolhatkar, 2008. Immediate implant placement: Clinical decisions, advantages, and disadvantages. *Journal of Prosthodontics*, **17**, 576–581.
- Botticelli, D., T. Berglundh, D. Buser & J. Lindhe, 2003. Positional bone formation in marginal defects at implants. An experimental study in the dog. *Clinical Oral Implant Research*, **14**, 1–9.
- Botticelli, D., T. Berglundh & J. Lindhe, 2004. Hard-tissue alterations following immediate implant placement in extraction sites. *Journal of Clinical Periodontology*, **31**, 820–828.
- Caneva, M., L. Salata, S. Souza, E. Bressan, D. Botticelli & N. Lang, 2010a. Hard tissue formation adjacent to implants of various size and configuration immediately placed into extraction sockets: An experimental study in dogs. *Clinical Oral Implant Research*, **21**, 885–890.
- Caneva, M., D. Botticelli, L. Salata, S. Souza, L. Cardoso & N. Lang, 2010b. Collagen membranes at immediate implants: A histomorphometric study in dogs. *Clinical Oral Implant Research*, **21**, 891–897.
- Carmagnola, D., T. Berglundh, M. Araujo, T. Albrektsson & J. Lindhe, 2000. Bone healing around implants placed in a jaw defect augmented with Bio-OssA. An experimental study in dogs. *Journal of Clinical Periodontology*, **27**, 799–805.
- Carmagnola, D., P. Adriaens & T. Berglundh, 2003. Healing of human extraction sockets filled with Bio-Oss. *Clin. Oral Impl. Res.*, **14**, 137–143.
- Indjova, J., D. Sivrev, H. Fakih, M. Paskalev & Ts. Chaprazov, 2013. Guided bone regeneration with xenografts and aloplasts (*in vivo* experiments in rabbits). *International Scientific Conference "90 Years Faculty of Veterinary Medicine in Bulgaria"*, 30–31 May 2013, Stara Zagora, Abstract Book, p. 57.
- Hallman, M., L. Sennerby & S. Lundgren, 2002. A clinical and histologic evaluation of implant integration in the posterior maxilla after sinus floor augmentation with autogenous bone, bovine hydroxyapatite, or a 20:80 mixture. *International Journal of Oral and Maxillofacial Implants*, **17**, 635–643.
- Hammerle, C., G. Chiantell, J. Karring & T. Lang, 1998. The effect of deproteinized bovine bone mineral on bone regeneration around titanium implants. *Clinical Oral Implant Research*, **9**, 151–162.
- Lang, N., U. Bragger, C. Hammerle & F. Sutter, 1994. Immediate transmucosal implants using the principle of guided tissue regeneration. I. Rationale, clinical procedures and 30-month results. *Clinical Oral Implant Research*, **5**, 154–163.
- Lundgren, D., H. Rylander & M. Andersson, 1992. Healing-in of root analogue titanium implants placed in extraction sockets. An experimental study in the beagle dog. *Clinical Oral Implant Research*, **3**, 136–143.
- Meredith, N., 1998. Assessment of implant stability as a prognostic determinant. *The International Journal of Prosthodontics*, **11**, 491–501.

- Piattelli, M., G. Favero, A. Scarano, G. Orsini & A. Piattelli, 1999. Bone reactions to anorganic bovine bone (Bio-Oss) used in sinus augmentation procedures: A histologic long-term report of 20 cases in humans. *International Journal of Oral and Maxillofacial Implants*, **14**, 835–840.
- Rabel, A., S. Köhler & A. Schmidt-Westhausen, 2007. Clinical study on the primary stability of two dental implant systems with resonance frequency analysis. *Clinical Oral Investigations*, **11**, 257–265.
- Rocci, A., M. Martignoni, P. Burgos, J. Gottlow & L. Sennerby, 2003. Histology of retrieved immediately and early loaded oxidized implants: Light microscopic observations after 5 to 9 months of loading in the posterior mandible. *Clinical Implant Dentistry and Related Research*, **5**, Suppl, 88–98.
- Roze, J., S. Babu, A. Saffarzadeh, M. Delacroix, A. Hoornaert & P. Layrolle, 2009. Correlating implant stability to bone structure. *Clinical Oral Implant Research*, **20**, 1140–1145.
- Scarano, A., M. Degidi, G. Iezzi, G. Petrone & A. Piattelli, 2006. Correlation between implant stability quotient and bone-implant contact: A retrospective histological and histomorphometrical study of seven titanium implants retrieved from humans. *Clinical Implant Dentistry & Related Research*, **8**, 218–222.
- Sennerby, L. & J. Roos, 1998. Surgical determinants of clinical success of osseointegrated oral implants. Review. *The International Journal of Prosthodontics*, **11**, 408–420.
- Sennerby, L., L. Persson, T. Berglundh, A. Wennerberg & J. Lindhe, 2005. Implant stability during initiation and resolution of experimental periimplantitis: An experimental study in the dog. *Clinical Implant Dentistry and Related Research*, **7**, 136–140.
- Sennerby, L. & N. Meredith, 2008. Implant stability measurements using resonance frequency analysis: Biological and biomechanical aspects and clinical implications. *Periodontology 2000*, **47**, 51–66.
- West, J. D. & T. Oates, 2007. Identification of stability changes for immediately placed dental implants. *International Journal of Oral and Maxillofacial Implants*, **22**, 623–630.
- Wilson, T. G. Jr, R. Schenk & D. Buser, 1998. Implants placed in immediate extraction sites: A report of histologic and histometric analyses of human biopsies. *International Journal of Oral and Maxillofacial Implants*, **13**, 333–341.

Paper received 25.06.2013; accepted for publication 11.09.2013

**Correspondence:**

Dr. Jermen Indjova  
Department of Oral and Maxillofacial Surgery,  
Faculty of Dental Medicine,  
Medical University – Sofia, Bulgaria,  
e-mail: indjovaj@yahoo.com