

Vertical Osteoconductive Characteristics of Titanium Implants with Calcium-Phosphate-Coated Surfaces – A Pilot Study in Rabbits

Eik Schiegnitz, MD;* Victor Palarie, DDS;† Viorel Nacu, MD, PhD;‡ Bilal Al-Nawas, MD, DMD, PhD;§ Peer Wolfgang Kämmerer, MD, DMD¶

ABSTRACT

Introduction: Osteoconductive characteristics of different implant surface coatings are in the focus of current interest. The aim of the present study was to compare the vertical osteoconductivity at the implant shoulder of supracrestal inserted calcium-phosphate coated implants (SLA-CaP) with conventional sand-blasted/acid-etched (SLA) implants in a rabbit model.

Materials and Methods: SLA-CaP and SLA implants were inserted bilaterally in the mandible of four rabbits in a split-mouth design. The implants were placed 2 mm supracrestal. After 3 weeks, at the left and right implant shoulder, the percentage of linear bone fill (PLF) as well as bone-implant contact (BIC-D) were determined.

Results: After 3 weeks, newly formed woven bone could be found at the shoulder of the most of both surface-treated implants (75%). PLF was significantly higher in SLA-CaP implants (11.2% vs. 46.5%; $n = 8$, $p = .008$). BIC-D was significantly increased in the SLA-CaP implants (13.0% vs. 71.4%; $n = 8$, $p < .001$) as well.

Conclusion: The results of this study show for the first time that calcium-phosphate coated surfaces on supracrestal inserted implants have vertical osteoconductive characteristics and increase the bone-implant contact at the implant shoulder significantly in a rabbit model. In clinical long-term settings, these implants may contribute to a better vertical bone height.

KEY WORDS: animal study, calcium-phosphate, implant, osteoconductive characteristics

*Department of Oral and Maxillofacial Surgery, Plastic Surgery, University Medical Center of the Johannes Gutenberg-University Mainz, Mainz, Germany; †State Medical and Pharmaceutical University “Nicolae Testemitanu”, Chisinau, Moldova, Clinic for Oral & Maxillofacial Surgery, Chisinau, Moldova; ‡State Medical and Pharmaceutical University “Nicolae Testemitanu”, Chisinau, Moldova, Clinic for Oral & Maxillofacial Surgery, Chisinau, Moldova; §Department of Oral and Maxillofacial Surgery, Plastic Surgery, University Medical Center of the Johannes Gutenberg-University Mainz, Mainz, Germany; ¶Department of Oral and Maxillofacial Surgery, Plastic Surgery, University Medical Center of the Johannes Gutenberg-University Mainz, Mainz, Germany

Reprint requests: Dr. Eik Schiegnitz, Department of Oral and Maxillofacial Surgery, Plastic Surgery, University Medical Centre of the Johannes Gutenberg-University. Augustusplatz 2, 55131 Mainz, Germany; e-mail: schiegnitz@gmx.com

The authors Schiegnitz and Palarie contributed equally in this study.

There are no commercial or other associations that might create a duality of interests in connection with the article.

© 2012 Wiley Periodicals, Inc.

DOI 10.1111/j.1708-8208.2012.00469.x

INTRODUCTION

The replacement of missing teeth by means of endosseous titanium implants has been proven to be an effective treatment for both completely and partially edentulous patients.¹⁻³ The adequate osseointegration of an implant is the unquestioned precondition for clinical success. However, the process of osseointegration is complex and various parameters influence the bone formation around dental implants: implant material, implant design, implant surface, status of bone, surgical technique, and the implant loading condition.^{4,5}

The most often used implant materials are commercially pure titanium and titanium alloys because of their excellent biocompatibility and biomechanical properties. The healing events leading to implant integration mainly occur in the tissue-implant interface.⁶ Being in direct contact with the bone and soft tissues of the host, the surface of implantable biomaterials plays a critical

role in determining biocompatibility as well as osseointegration.⁷ Surface modifications may change the morphologic surface characteristics and affect cellular events present at the interface^{8,9} leading to different outcomes on rate and amount of new bone formation. Accordingly, it was shown that surface modifications of titanium implants may have the potential to support bone formation at deficient sites such as circumferential defects,^{10,11} dehiscence-type defects,^{12,13} and supraalveolar ridge defects.¹⁴

Calcium-phosphate (CaP), mainly hydroxyapatite, is the main anorganic element of native bone. Coating with CaP is one of the strategies used in order to improve the surface characteristics of titanium. The bioactivity of hydroxyapatite is due to a chemical cohesive bonding of the apatitic coat with the surrounding osseous tissue through ion exchange.¹⁵ This exchange osteogenesis enables bidirectional bone formation on both, osseous recipient site and CaP coating.¹⁶ Recently, an implant system with an adhesive CaP coating (Bioactive®) was provided (Figure 1). Bioactive coating is a newly developed electrochemical process for the coating of dental implants in an aqueous solution containing calcium and phosphate ions. According to the manufacturer's data, the resorbable CaP coating has a low coating thickness of 20–30 µm, a micro-crystalline structure with a large active surface, and microporosity with high capillarity effect on blood. A clinical study indicated a promising 1-year survival and success rates



Figure 1 Calcium-phosphate-coated (Bioactive®) Implant (SLA-CaP).

for this system, although not better than for conventional implants.¹⁷ The implant material consists of a 5-grade titanium alloy with a sandblasted and etched microstructure, internal hexagon, spiral, conical, self-drilling, self-tapping, double-thread system, with deep and especially sharp threads decreasing toward the implant shoulder, enabling implant self-retention and aiming for high primary stability.

It may be hypothesized that the CaP coating could have osteoconductive characteristics, consequently enhancing the mechanical fixation and reducing total implant healing time. Therefore, the aim of this study was to compare the vertical osteoconductivity and the percentage of bone to implant contact at the implant shoulder of supracrestal-inserted titanium implants (CaP-coated and conventional sandblasted/acid-etched surfaces) in a rabbit model.

MATERIALS AND METHODS

Implants

All implants used in the study were from Alfa Gate Dental Implants (3.5 mm × 6 mm; Kfar Qara, Israel). The implants were either large grit-sandblasted, acid-etched and coated electrochemically with CaP (SLA-CaP; Figure 1) or large grit-sandblasted and acid-etched (SLA) only.

Animals

The study was performed on four adult New Zealand White rabbits (9 months old) weighing approximately 4–5 kg. After approval of the ethics committee, the surgical part of the project was made at the State University of Medicine and Pharmacy “N. Testemitanu,” Chisinau, Moldova. The rabbits were treated in accordance with both policies and principles of laboratory animal care and with the European Union guidelines (86/609/EEC). The animals were housed separately under laboratory conditions at a room temperature of 20–22° and humidity between 30 and 50%. The room temperature and humidity were monitored daily. During the acclimation and observation period (at least 7 days), all animals were fed a standard diet, were allowed free mobilization, and had free access to water. Surgeries were performed using aseptic routines. A combination of ketamine (35 mg/kg) and xylazine (5 mg/kg) was administered by intramuscular injections to induce anesthesia.

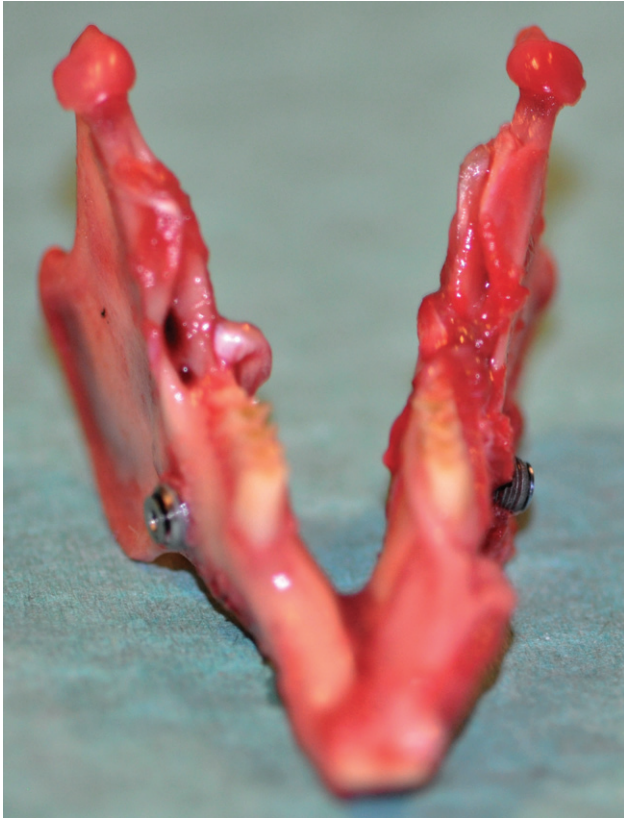

Figure 2 Clinical pictures of dental implants inserted supracrestally into the lateral mandible of a rabbit in a split-mouth design.

Surgical Procedure

The rabbits underwent routine oral disinfection procedures, which implied tongue cleaning, irrigation, and rinsing with chlorhexidine (0.2%) before the surgical procedure. Calcium phosphate-coated (SLA-CaP) or conventional sandblasted/acid-etched (SLA) implants were inserted via extraoral approach bilaterally according to a split-mouth design in the lateral mandible of the rabbits (Figure 2). The implants were placed 2 mm supracrestal. Implants were inserted according to the manufacturer's instructions under permanent external saline irrigation. Standard cover screws were mounted and the flaps were sutured. The sutures were removed 10 days postoperatively.

Histological Preparation

Animals were sacrificed with an intravenous overdose of pentobarbital 3 weeks after surgery (100 mg/kg). The samples were fixated with 4% paraformaldehyde. Implants and their surrounding tissues were removed *en bloc*, immersed for 4 weeks, and prepared for histological

examination like previously described in detail.^{18,19} In brief, the specimens were cut down by a commercial water-cooled saw (Exakt, Hamburg, Germany) to a thickness of 5 mm perpendicular to the axis of the placed dental implants. The bone slices were immediately given in polymethyl methacrylate (Technovit 7100, Heraeus Kulzer, Hanau, Germany) and then cut to a thickness of 30 to 50 μm . The specimens were stained with toluidine blue. For histomorphometric measurement, all slides were digitalized.

Histomorphometric Analysis

A Leica DM8000 M microscope (Leica Microsystems, Heidelberg, Germany) was used to take images from the slides. The digitalized images were histomorphometric analyzed with the software program ImageJ. ImageJ can calculate area and pixel value statistics of user-defined selections and is widely used for medical and scientific image analysis. With this program, a high accuracy of the PIF and bone-implant contact (BIC-D) measurements is possible. Measurements were performed on digitized images at a magnification of $\times 10$.

Percentage Linear Bone Fill (PLF)

At the left and right implant shoulder, the PLF was determined. For this, the relation between the total volume and the new formed bone in a $1.5 \text{ mm} \times 1.5 \text{ mm}$ region of interest was evaluated (Figures 3 and 4). Total values were calculated.

Percentage of Bone to Implant Contact (BIC-D)

BIC-D at the implant shoulder was calculated as the length of implant surface in direct apposition to bone

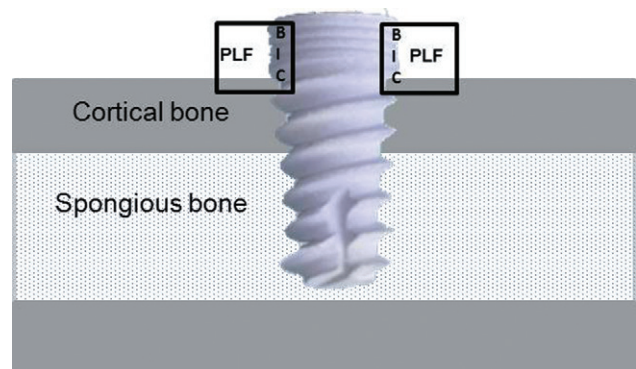


Figure 3 Schema of the supracrestal-inserted implant together with the determined parameters percentage linear bone fill (PLF) and the percentage of bone to implant contact (BIC).

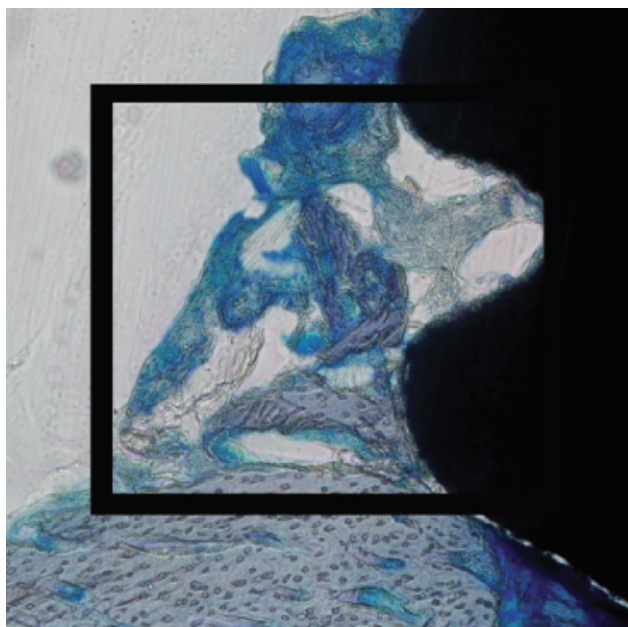


Figure 4 Measurement of PLF and BIC on a digitalized histological sample (toluidine blue, $\times 10$).

out of the implant surface at the implant shoulder $\times 100\%$ (Figures 3 and 4). Bone contact was defined as intimate interface contact between the bone and the implant surface, with no soft tissue visible in between.

Statistical Analysis

Statistical analysis was performed with nonparametric tests by using the software package of IBM SPSS Statistics 19.0 for Windows (IBM, Armonk, NY, USA). For all parameters, the left and the right implant shoulder was examined. The nature of this experiment was exploratory; therefore, we report descriptive p values of tests. p values of $p \leq .05$ were termed to be significant.

RESULTS

The postoperative healing was generally uneventful. All the four animals completed the study and could be included in the descriptive statistical analysis. No complications such as fractures, allergic reactions, swellings, abscesses, or infections were noticed throughout the entire study period. Clinically and radiographically, all implants seemed to be osseointegrated at animal sacrifice.

Histomorphometric Analysis

Descriptive Analysis. New supracrestal bone was seen after 3 weeks in 3/4 SLA-CaP (75%) and in 3/4 SLA

implants (75%). In all cases, bone was growing in a triangle with its basis on the underlying cortical bone toward the implant (Figure 5).

PLF. After 3 weeks, newly formed woven bone could be found histologically around the implant shoulder of most of the implants. The SLA-CaP implants caused a PLF of $46.5 \pm 24.0\%$ (Figure 5). A PLF of $11.2 \pm 17.0\%$ was measured for the noncoated SLA implants (Figure 6). There was a significant difference between the two groups ($p = .008$; $n = 8$; Figure 7).

BIC-D. Histomorphometric analysis further showed that BIC-D at the shoulder area was $71.4 \pm 23.8\%$ for SLA-CaP implants and $13.0 \pm 20.7\%$ for SLA implants. BIC-D of the CaP-coated implants was significantly higher compared to the noncoated implants ($p < .001$; $n = 8$; Figure 8).

DISCUSSION

In the present study, an evaluation of the vertical osteoconductivity of electrochemically CaP-coated implant surfaces compared to mechanically altered implants was

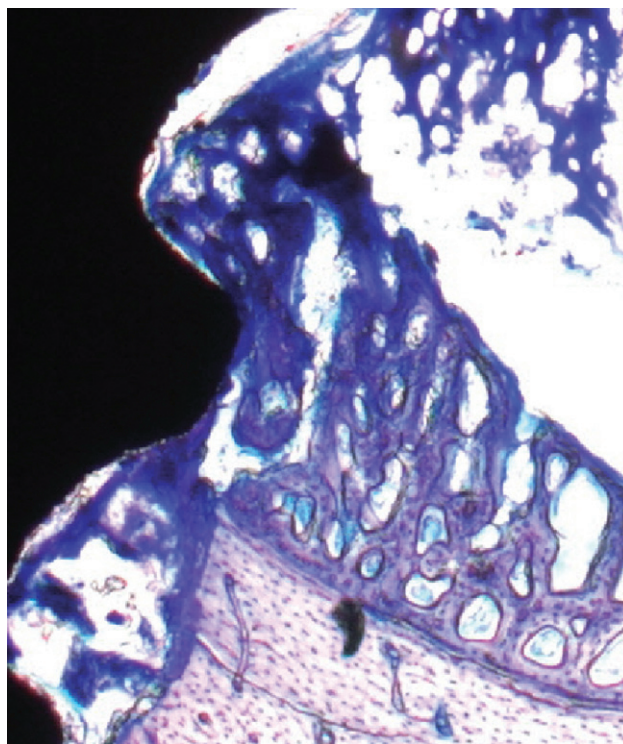


Figure 5 Representative histological specimen (toluidine blue, original magnification $\times 10$) showing the new bone growth after 3 weeks at the implant shoulder of a SLA-CaP implant.

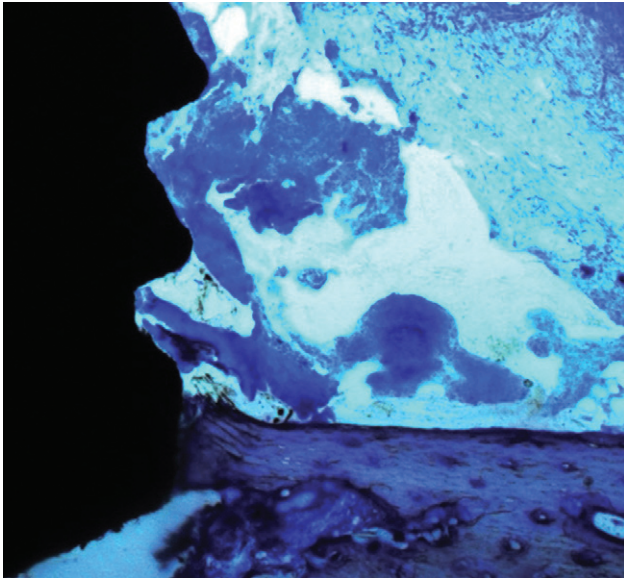


Figure 6 Representative histological specimen (toluidine blue, original magnification $\times 10$) showing the new bone growth after 3 weeks at the implant shoulder of a SLA-CaP implant.

conducted. We are able to demonstrate that CaP implants significantly enhance PLF and BIC-D compared with the conventional surfaces in a rabbit mandible model. These results indicate for the first time that CaP-coated surfaces on supracrestal-inserted implants may have osteoconductive characteristics at the implant shoulder and support the concept that bioactive

CaP-coated implants may have the capacity to guide supracrestal bone growth.²⁰ The use of rabbit models has been recommended by different authors^{21–23} as a beneficial tool to test implant surface characteristics. The lateral mandible model was evaluated before in several animals²⁴ and can therefore be seen to be suitable. We used a two-dimensional histomorphometric analysis in this study. To date, two-dimensional histomorphometry is the gold standard of evaluation of specimens, and we compared our data with other studies that used the same techniques. For future research, a three-dimensional evaluation via micro-computed tomography could be an interesting approach to analyze the implant and its surrounding tissue.

The initial interaction between biomaterial and biological environment after implantation takes place at the surface. There are a number of surfaces commercially available for dental implants; the exact role of surface chemistry and topography on the early events of the osseointegration is under current examination.^{25–27} One of the concepts used to enhance osseointegration is to create bioactive surfaces, thus promoting bone–tissue reactions at the interface. Titanium is basically considered to be bioinert and not likely to form direct bonds with bone, so a bioactive material, coated onto the surfaces of Ti implant, could increase optimal surface reactivity. The bioactive CaP coating induces the forming of

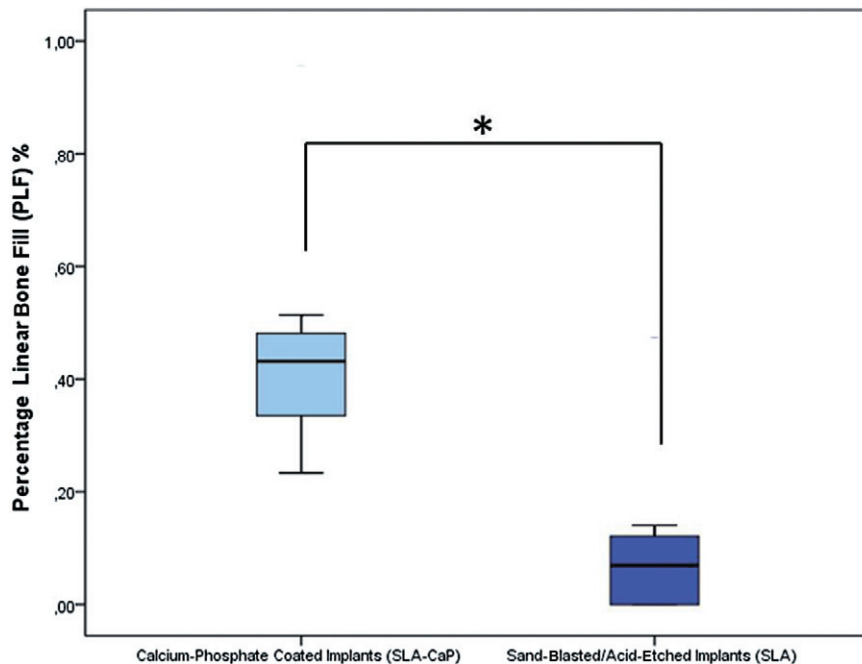


Figure 7 Boxplots showing the percentage linear bone fill (PLF) after 3 weeks (0 = 0%, 1 = 100%; $*p = .008$; $n = 8$).

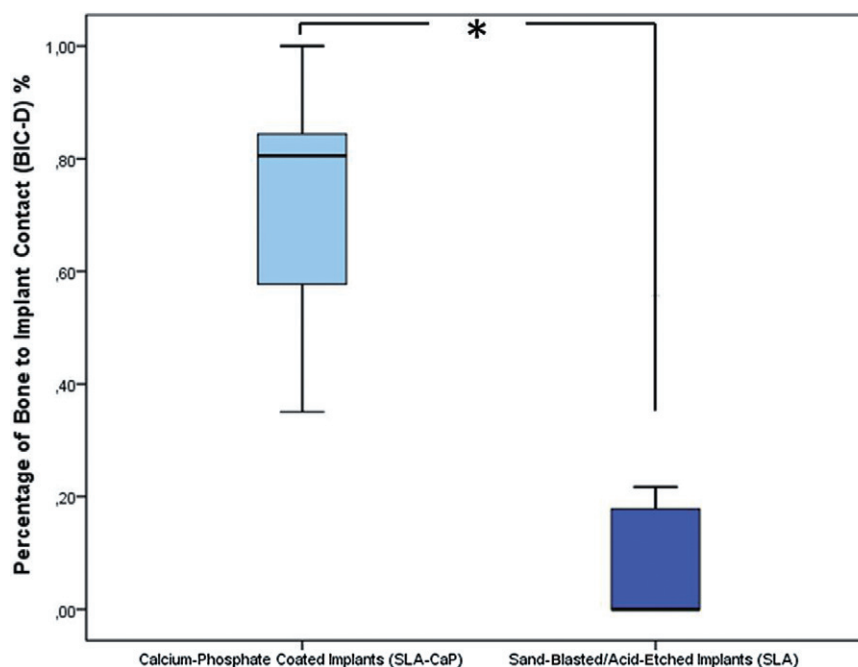


Figure 8 Boxplots showing the percentage of bone to implant contact after 3 weeks (0 = 0%, 1 = 100%; * $p < .001$; $n = 8$).

enlarged structures covering even complicated implant shapes together with an increased solubility and a controlled absorption rate of calcium and phosphate ions during the first healing period of osseointegration.²⁸ Our results are in consensus with other studies that showed an improved early osseointegration of CaP coatings when compared with commercially pure titanium surfaces.²⁹⁻³¹ The study from Webster and coworkers demonstrated that calcium titanate promoted osteoblast adhesion, and proposed CaTiO_3 as a strong candidate for increasing osseointegration.³² The effects of a nanostructured calcium coating on the surfaces of blasted Ti implants on peri-implant bone formation in the rabbit tibiae were assessed. It could be deduced that CaP-coated surfaces may improve osseointegration, probably due to the biologically active surface chemistry.³³ Other groups could also show better outcomes of the CaP-coated surfaces compared with blasted surfaces in poor-quality bone.³⁴ In contrast, histological investigation of Fontana and colleagues showed that the CaP coating had no beneficial effect in improving bonding strength at the bone-implant interface in a rabbit model.³⁵ The discrepancy of these results may be due to several factors such as a different surgical protocol applied, a different animal model, or a different technique in CaP coating. The electrochemical deposition technique in the present study results in a more soluble CaP envelope than

plasma-sprayed coatings. Theoretically, a higher CaP solubility may increase the initial bone response.³⁶ In addition, potential disadvantageous long-term effects such as coat fractures with subsequent implant failure may be prevented if the CaP coat is gradually resorbed and replaced by bone tissue. Nevertheless, it has to be kept in mind, that theoretically, this resorption may lead to reduced stability in the remodeling phase. This possible effect of gradual resorption of CaP-coated surfaces was not in the center of the present study and was not evaluated after 3 weeks. Longer-term studies could eventually show different vertical osteoconductive characteristics of CaP-coated titanium implants. Therefore, further studies needed to examine this effect. Although no negative affection, even after early implant loading, was seen in a clinical study.³⁷

Several studies indicated that an enhanced calcium composition in the outer oxide layer can improve cell adhesion on titanium surfaces by increasing protein adsorption.³⁴ Following implantation, the release of CaP into the peri-implant zone raises the saturation of body fluids and releases a biological apatite onto the surface of the implant.³⁸ This layer of biological apatite might include endogenous proteins and provides a matrix for osteogenic cell attachment and growth.³⁹ Consequently, this biological apatite layer improves the bone healing process around the implant and accelerates the

biological fixation of titanium implants to bone tissue.⁴⁰ This may explain better or at least equivalent clinical long-term success rates for CaP coatings compared to uncoated titanium implants.^{37,41}

CONCLUSION

In conclusion, the histomorphometric results of this study indicate that the bioactive surface chemistry of CaP coating may provide potential synergic effects for peri-implant bone formation around endosseous titanium implants. It could be shown that CaP-coated surfaces on supracrestal-inserted implants have osteoconductive characteristics in a rabbit model. Additional studies are needed to validate these preliminary data, especially toward a possible increase of vertical bone height, an increased initial stability and subsequent higher clinical success.

REFERENCES

- Jemt T, Chai J, Harnett J, et al. A 5-year prospective multicenter follow-up report on overdentures supported by osseointegrated implants. *Int J Oral Maxillofac Implants* 1996; 11:291–298.
- Lindquist LW, Carlsson GE, Jemt T. A prospective 15-year follow-up study of mandibular fixed prostheses supported by osseointegrated implants. Clinical results and marginal bone loss. *Clin Oral Implants Res* 1996; 7:329–336.
- Lambrecht JT, Filippi A, Kunzel AR, Schiel HJ. Long-term evaluation of submerged and nonsubmerged ITI solid-screw titanium implants: a 10-year life table analysis of 468 implants. *Int J Oral Maxillofac Implants* 2003; 18:826–834.
- Kumar V, Sagheb K, Klein MO, Al-Nawas B, Kann PH, Kämmerer PW. Relation between bone quality values from ultrasound transmission velocity and implant stability parameters – an ex-vivo study. *Clin Oral Imp Res* 2011. DOI: 10.1111/j.1600-0501.2011.02250.x. [Epub ahead of print].
- Herrmann I, Lekholm U, Holm S, Kultje C. Evaluation of patient and implant characteristics as potential prognostic factors for oral implant failures. *Int J Oral Maxillofac Implants* 2005; 20:220–230.
- Puleo DA, Nanci A. Understanding and controlling the bone-implant interface. *Biomaterials* 1999; 20:2311–2321.
- Al-Nawas B, Wagner W, Grotz KA. Insertion torque and resonance frequency analysis of dental implant systems in an animal model with loaded implants. *Int J Oral Maxillofac Implants* 2006; 21:726–732.
- Klein MO, Bijelic A, Ziebart T, et al. Submicron scale-structured hydrophilic titanium surfaces promote early osteogenic gene response for cell adhesion and cell differentiation. *Clin Implant Dent Relat Res* 2011. DOI: 10.1111/j.1708-8208.2011.00339.x. [Epub ahead of print].
- Kämmerer PW, Heller M, Brieger J, Klein MO, Al-Nawas B, Gabriel M. Immobilization of linear and cyclic RGD-peptides on titanium surfaces and their impact on endothelial cell adhesion and proliferation. *Eur Cell Mater* 2011; 11:364–372.
- Lai HC, Zhuang LF, Zhang ZY, Wieland M, Liu X. Bone apposition around two different sandblasted, large-grit and acid-etched implant surfaces at sites with coronal circumferential defects: an experimental study in dogs. *Clin Oral Implants Res* 2009; 20:247–253.
- Vignoletti F, de Sanctis M, Berglundh T, Abrahamsson I, Sanz M. Early healing of implants placed into fresh extraction sockets: an experimental study in the beagle dog. III: soft tissue findings. *J Clin Periodontol* 2009; 36:1059–1066.
- Schwarz F, Herten M, Sager M, Wieland M, Dard M, Becker J. Bone regeneration in dehiscence-type defects at chemically modified (SLActive) and conventional SLA titanium implants: a pilot study in dogs. *J Clin Periodontol* 2007; 34:78–86.
- Schwarz F, Rothamel D, Herten M, et al. Immunohistochemical characterization of guided bone regeneration at a dehiscence-type defect using different barrier membranes: an experimental study in dogs. *Clin Oral Implants Res* 2008; 19:402–415.
- Wikesjö UM, Qahash M, Polimeni G, et al. Alveolar ridge augmentation using implants coated with recombinant human bone morphogenetic protein-2: histologic observations. *J Clin Periodontol* 2008; 35:1001–1010.
- Strnad Z, Strnad J, Povysil C, Urban K. Effect of plasma-sprayed hydroxyapatite coating on the osteoconductivity of commercially pure titanium implants. *Int J Oral Maxillofac Implants* 2000; 15:483–490.
- Weinlaender M. Bone growth around dental implants. *Dent Clin North Am* 1991; 35:585–601.
- Palarie V, Bicer C, Lehmann KM, Zahalka M, Draenert FG, Kammerer PW. Early outcome of an implant system with a resorbable adhesive calcium-phosphate coating – a prospective clinical study in partially dentate patients. *Clin Oral Investig* 2010. DOI: 10.1007/s00784-011-0598-8. [Epub ahead of print].
- Donath K, Breuner G. A method for the study of undecalcified bones and teeth with attached soft tissues. The Sage-Schliff (sawing and grinding) technique. *J Oral Pathol* 1982; 11:318–326.
- Wagner W, Tetsch P, Ackermann KL, Bohmer U, Dahl H. Animal experimental studies on bone regeneration in standardized defects after the implantation of tricalcium phosphate ceramic. *Dtsch Zahnarzt Z* 1981; 36:82–85.
- Bose S, Tarafder S. Calcium phosphate ceramic systems in growth factor and drug delivery for bone tissue engineering: a review. *Acta Biomater* 2012; 8:1401–1421.
- Sennerby L, Dasmah A, Larsson B, Iverhed M. Bone tissue responses to surface-modified zirconia implants: a

- histomorphometric and removal torque study in the rabbit. *Clin Implant Dent Relat Res* 2005; 7 (Suppl 1):S13–S20.
22. Susin C, Qahash M, Hall J, Sennerby L, Wikesjo UM. Histological and biomechanical evaluation of phosphorylcholine-coated titanium implants. *J Clin Periodontol* 2008; 35:270–275.
 23. Draenert FG, Kammerer PW, Palarie V, Wagner W. Vertical bone augmentation with simultaneous dental implantation using crestal biomaterial rings: a rabbit animal study. *Clin Implant Dent Relat Res* 2012; 14 (Suppl s1):e169–e174.
 24. Freilich M, Shafer D, Wei M, Kompalli R, Adams D, Kuhn L. Implant system for guiding a new layer of bone. *Computed microtomography and histomorphometric analysis in the rabbit mandible. Clin Oral Implants Res* 2009; 20:201–207.
 25. Meirelles L, Uzumaki ET, Lima JH, et al. A novel technique for tailored surface modification of dental implants – a step wise approach based on plasma immersion ion implantation. *Clin Oral Implants Res* 2011. DOI: 10.1111/j.1600-0501.2011.02352.x. [Epub ahead of print].
 26. Schlegel KA, Prechtel C, Most T, Seidl C, Lutz R, von Wilmowsky C. Osseointegration of SLActive implants in diabetic pigs. *Clin Oral Implants Res* 2011. DOI: 10.1111/j.1600-0501.2011.02380.x. [Epub ahead of print].
 27. de Barros RR, Novaes AB Jr, Queiroz A, de Almeida AL. Early peri-implant endosseous healing of two implant surfaces placed in surgically created circumferential defects. A histomorphometric and fluorescence study in dogs. *Clin Oral Implants Res* 2011. DOI: 10.1111/j.1600-0501.2011.02357.x. [Epub ahead of print].
 28. Zeggel P. Bioactive calcium phosphate coatings for dental implants. *Int Mag Oral Implant* 2000; 1:52–57.
 29. Caulier H, van der Waerden JP, Wolke JG, Kalk W, Naert I, Jansen JA. A histological and histomorphometrical evaluation of the application of screw-designed calciumphosphate (Ca-P)-coated implants in the cancellous maxillary bone of the goat. *J Biomed Mater Res* 1997; 35:19–30.
 30. Karabuda C, Sandalli P, Yalcin S, Steflik DE, Parr GR. Histologic and histomorphometric comparison of immediately placed hydroxyapatite-coated and titanium plasma-sprayed implants: a pilot study in dogs. *Int J Oral Maxillofac Implants* 1999; 14:510–515.
 31. Mohammadi S, Esposito M, Hall J, Emanuelsson L, Krozer A, Thomsen P. Short-term bone response to titanium implants coated with thin radiofrequent magnetron-sputtered hydroxyapatite in rabbits. *Clin Implant Dent Relat Res* 2003; 5:241–253.
 32. Webster TJ, Ergun C, Doremus RH, Lanford WA. Increased osteoblast adhesion on titanium-coated hydroxylapatite that forms CaTiO₃. *J Biomed Mater Res A* 2003; 67:975–980.
 33. Suh JY, Jeung OC, Choi BJ, Park JW. Effects of a novel calcium titanate coating on the osseointegration of blasted endosseous implants in rabbit tibiae. *Clin Oral Implants Res* 2007; 18:362–369.
 34. Jansen JA, van der Waerden JP, Wolke JG. Histologic investigation of the biologic behavior of different hydroxyapatite plasma-sprayed coatings in rabbits. *J Biomed Mater Res* 1993; 27:603–610.
 35. Fontana F, Rocchietta I, Addis A, Schupbach P, Zanotti G, Simion M. Effects of a calcium phosphate coating on the osseointegration of endosseous implants in a rabbit model. *Clin Oral Implants Res* 2010; 22:760–766.
 36. Ducheyne P, Beight J, Cuckler J, Evans B, Radin S. Effect of calcium phosphate coating characteristics on early post-operative bone tissue ingrowth. *Biomaterials* 1990; 11:531–540.
 37. Palarie V, Bicer C, Lehmann KM, Zahalka M, Draenert FG, Kammerer PW. Early outcome of an implant system with a resorbable adhesive calcium-phosphate coating – a prospective clinical study in partially dentate patients. *Clin Oral Investig* 2011. DOI: 10.1007/s00784-011-0598-8. [Epub ahead of print].
 38. Daculsi G, Laboux O, Malard O, Weiss P. Current state of the art of biphasic calcium phosphate bioceramics. *J Mater Sci Mater Med* 2003; 14:195–200.
 39. Davies JE. Understanding peri-implant endosseous healing. *J Dent Educ* 2003; 67:932–949.
 40. Barrere F, van der Valk CM, Meijer G, Dalmeijer RA, de Groot K, Layrolle P. Osteointegration of biomimetic apatite coating applied onto dense and porous metal implants in femurs of goats. *J Biomed Mater Res B Appl Biomater* 2003; 67:655–665.
 41. Geurs NC, Jeffcoat RL, McGlumphy EA, Reddy MS, Jeffcoat MK. Influence of implant geometry and surface characteristics on progressive osseointegration. *Int J Oral Maxillofac Implants* 2002; 17:811–815.